



MOVING AHEAD

A Swanson Regional Orthotic & Prosthetic Research Center Publication No. 54

O&P Care for the Diabetic Patient

Prosthetists, orthotists and pedorthists in the United States see more older patients with diabetes than any other presenting condition. If any patient type can be described as the “bread and butter” of O&P practice, this would be it.

Despite decades of progress in managing diabetes, the course of this disease still frequently culminates in various degrees of lower-limb morbidity and ultimately lower-extremity amputation for older patients. Statistics published by the American Diabetes Association indicate that more than 60 percent of non-traumatic lower-limb amputations in the United States occur among people with diabetes and that from 2000 to 2001 an estimated 82,000 non-traumatic lower-limb amputations were performed annually on people with the disease. Vascular insufficiency secondary to diabetes is the most frequently cited cause.

While amputation of a part of a lower limb may be a sound therapeutic decision, it does not resolve the host of conditions that likely prompted the amputation in the first place for the aging diabetic: ischemia and/or neuropathy in the lower limb, generalized muscle weakness, lack of coordination and balance, and visual and cognitive impairments. Thus, continuing aggressive management of these conditions with the O&P practitioner as an involved participant remains an important management strategy.

unresolved can quickly lead to plantar ulcerations, often the first insult in a series of events leading to amputation.

The primary weapon against plantar ulcers, and thus lower limb amputation, for the diabetic patient is properly prescribed and fabricated therapeutic footwear—including specially constructed shoes, modifications, and custom-molded inserts. (See article, page 2).

Other orthotic measures include supportive and protective componentry for specific conditions, such as custom-molded ankle-foot orthoses (AFOs) and the Charcot Restraint Orthotic Walker.



Courtesy, Otto Bock Health Care.

(Continued on page 2)



Custom-molded AFO

Protecting the Insensate Foot

Our practitioners provide specialist support for diabetic patients, both to achieve the most positive functional outcome possible for those who have undergone an amputation and to protect those with intact lower limbs from future limb loss. (Another disturbing statistic reveals that more than 50 percent of surviving diabetic amputees will lose their remaining lower limb within four years.)

O&P concern for diabetic patients, whether or not they have already undergone an amputation, stresses sound foot management through regular careful observation, patient education and orthotic-pedorthic support. The goal is to prevent high plantar pressures and trauma, which

About Moving Ahead

Moving Ahead is a professional newsletter published by Swanson Regional Orthotic & Prosthetic Research Center to inform health care professionals of developments in the orthotic and prosthetic disciplines.

Swanson offers three board-certified practitioners and three state-of-the-art laboratories. The practice has a solid reputation for quality care and patient satisfaction throughout Northwest Ohio and Southeast Michigan and has been in business for more than 24 years.

To tour our well-equipped facilities or be added to our mailing list, please write or call:

Swanson Regional Orthotic & Prosthetic Research Center
3102 Sylvania Ave. • Toledo, OH 43613 • (419) 472-8910
124 Cole Rd. • Monroe, MI 48162 • (313) 241-4397
735 S. Shoop Ave., Ste. 3 • Wauseon, OH 43567 • (419) 335-6400
Visit us online: www.swansonopcenter.com

Compliments of: Vern Swanson, C.P.; and Jon S. Eberlein, CPO.


Diabetes Involves the Full Spectrum of

(Continued from page 1)

In the case of unilateral diabetic amputees, it is not uncommon to have rigorous orthotic-pedorthic management under way for the non-amputated leg while active prosthetic care is in progress. Such is particularly the case during the period of extensive gait training that accompanies the recent amputee's transition to prosthetic ambulation, when considerable additional loading is applied to the remaining foot's plantar surface.

Prosthetic Considerations

When, despite the best efforts of the management team, amputation becomes unavoidable, our role grows to encompass prosthetic management, provided the patient can indeed benefit from a prosthetic limb. The recuperating patient must possess several prerequisite capabilities to advance to prosthetic use, notably the ability to rise from bed or chair and pivot on the contralateral limb and sufficient hand and arm strength to maneuver the prosthetic components. These prerequisites require a level of balance and cognition deemed adequate by the rehabilitative team.



Courtesy, Ohio Willow Wood.

Slow wound healing is a hallmark of advanced diabetes, especially in the lower limb. Complications of surgery can include infection, edema and possibly further compromise to the existing vascular insufficiency. A commonly accepted guideline is to begin the transition to a prosthesis about six weeks post-op, barring continuing complications.

One approach is to provide a preparatory, or training, limb when the wound has sufficiently healed and all lingering signs of edema and infection have been resolved. This is a relatively simple and inexpensive device, which enables the rehabilitative team to assess ambulation potential. When the amputee's strength returns and the diabetes is under reasonable control, transition to a definitive prosthesis can commence.

Another method is to provide definitive limb components from the outset, then provide a new socket when the residual limb matures, four to eight months later. This course enables the use of more advanced components up front and eliminates the need to retrain the patient in the use of a different, more capable prosthesis after the preparatory period.

In conjunction with participating physicians and therapists, we will design and fabricate the most appropriate and functional prosthetic system for our diabetic patients while continuing to provide meticulous care and monitoring of the residual limb.

Prosthetic Componentry

Light weight, durability and ease of use are important attributes in all prosthetic applications but particularly so in lower-limb systems for diabetic patients.

The socket interface between the residual limb and prosthesis must not exacerbate ischemic deficiency, and the weight, control and propulsion requirements of the system cannot exceed the strength, coordination and endurance limits of the new amputee. Epoxy resins, carbon fibers, titanium, aluminum alloys and thermoplastics are materials of choice.

Sockets and Liners—Because sores and infection occur so frequently in insensate limbs, sockets and liners are key determinants of prosthetic success. Flexible, dynamic sockets expand and contract with the musculature of the limb, preventing undue pressure over sensitive skin or nerve areas and bony prominences. Silicone and urethane gel sockets and liners can reduce friction and skin irritation and increase tolerance for the forces exerted within the socket. Many of



Liners help protect tissue from friction
Courtesy, Ohio Willow Wood

First Line of Defense

Statistics tell a disturbing tale of diabetic foot complications in this country:

- More than 25 percent of the estimated 18 million people with diabetes in the U.S. will develop significant foot problems.
- Foot problems account for 20 percent of all diabetes-related hospitalizations.
- People with diabetes are *five times* more likely to develop gangrene than non-diabetics.
- Diabetics are 15 times more likely to require a limb amputation than the general population.

Therapeutic
Footwear

No Pain, No Gain

One thing we've learned in working with diabetic patients over the years: Never ask how their feet feel, because in many cases they honestly don't know.

People with diabetes in particular are prone to peripheral neuropathy and may have virtually no sensation in their feet. As a result, tissues already overly susceptible to poor circulation, infection and skin damage may give no warning when a developing crisis is being exacerbated with every step.

In the diabetic foot, skin breakdown can result from a single high-stress event, such as stepping barefoot on a sharp or blunt object; from ischemia, typically caused by tight-fitting shoes; or, most commonly, from the repetitive moderate stress of everyday walking. A common outcome is ulcers on the plantar surface under the metatarsal heads.

Without aggressive treatment, superficial lesions can quickly degenerate to deep ulcers involving tendon and bone. Further

f Prosthetic and Orthotic Capabilities

today's liners incorporate suction suspension or locking devices that replace older suspension methods.

Knee System—For above-knee diabetic amputees, a light-weight knee component providing a high degree of stability is usually prescribed. Polycentric designs incorporating a moving center of rotation keyed to the degree of knee flexion are an excellent choice. Older patients also may require the additional support of a locking device to prevent knee buckling while standing.

Pylon—Most lower-limb systems for diabetic patients are of the endoskeletal variety with a cosmetic cover. The shank, or pylon, is typically made of high-strength, lightweight metal or carbon-fiber alloy.

Ankle-Foot Complex—Lightweight feet appropriate to the amputee's activity level will maximize the benefit the older diabetic patient receives from any prosthetic limb. Components

made especially for older seniors include the Endolite Senior Foot and Otto Bock Geriatric Lightfoot. Ossur's Sure-Flex and the still-

reliable SACH (solid ankle, cushion heel) foot are other good choices. In most instances, more advanced dynamic-response and carbon-fiber feet are appropriate only for patients known to be capable of maintaining an active lifestyle.

Follow-up

Diabetic amputees present additional challenges and thus require more frequent prosthetic care than most other individuals with a limb deficiency. For example, diabetic patients frequently experience a reduction in perspiration and loss of skin moisture, leaving residual limb tissue prone to skin breakdown and infection. Thus, regular inspection of the residual limb and adjoining skin surfaces is an essential follow-up regimen.

Our practitioners are dedicated to providing the best possible outcome for our diabetic patients and working with other health professionals in aggressively managing diabetes symptoms and risk factors. We are available to help with componentry problems as they occur and to assist patients in achieving the compliance necessary for management success. We consider patient education a major component of our patient care role.

For additional information, give us a call.



ect residual limb
and irritation.
Willow Wood.

sense for Diabetic Feet

deterioration can yield an abscess, osteomyelitis and ultimately gangrene and amputation. Diabetes is also the most prevalent factor in the development of neuropathic arthropathy, frequently resulting in foot and ankle deformities.


The goals of therapeutic footwear are to provide even pressure distribution across the plantar surface, eliminate focused stress areas, afford shock absorption and foster proper foot mechanics. While foot orthoses can be designed to correct certain deformities, the primary role of special footwear for diabetic patients is to provide an advanced level of protection for the insensate foot.

Shoes

General considerations for diabetic shoes include low heels, a spacious, rounded toe box, well-cushioned heel and sole, and soft uppers that can mold to the shape of the patient's foot.

Shoes with extra depth throughout are commonly prescribed to allow insertion of a molded foot (FO) or ankle-foot (AFO) orthosis or to accommodate minor deformities. For advanced diabetes and gross deformities, shoes or boots custom-molded to a model of the patient's foot are generally necessary.

Therapeutic shoes are widely available in a variety of styles and colors. Advanced thermoplastic materials, such as low-temperature *plastazote* foam, have contributed to improved therapeutic shoe design and performance.



Courtesy, Apex Foot Health Industries.

Inserts and Modifications

Custom-molded orthotic inserts and special modifications are added to shoes to provide for specific anatomical, functional and protective needs.

They are formed to a model of the patient's foot to protect against focused stresses and to accommodate minor deformities. They are typically made from lightweight-but-durable materials and can be easily removed and replaced when necessary.

Shoe modifications for diabetic patients—e.g. arch supports, metatarsal bars, rocker bottoms, toe-fillers, heel counters, and heel and sole wedges—are used to relieve pressures under the metatarsal heads, provide advanced protection for the plantar surface and assist full heel-to-toe gait after a partial foot amputation. Special modifications may also be applied to accommodate Charcot joint deformities resulting from diabetes-related arthropathy.

Bottom Line

When it comes to diabetes management, one (shoe) size definitely does not fit all. We welcome your inquiries about diabetic footwear and recommendations for individual patients.

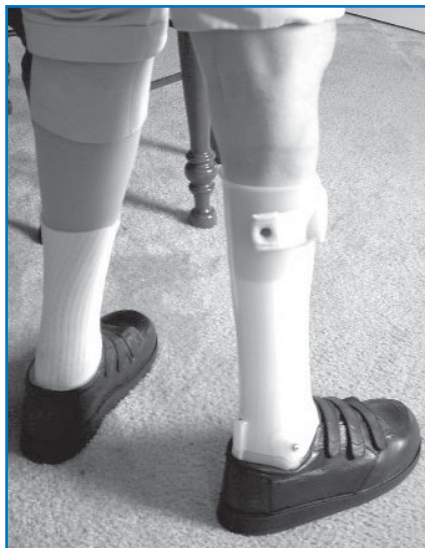

Courtesy, Soletech.

Down to Cases

Managing a Typically Challenging Diabetic Patient

Philip, 74, whose diabetes is complicated by osteomyelitis and significant visual impairment, is illustrative of the spectrum of rehabilitation challenges often presented by older diabetic patients. He presented wearing a well-worn right below-knee prosthesis and left dorsiflexion-assist metal short leg



Philip tries out new prosthesis on left limb, new AFO and shoe on right.

brace and complaining of poor fit, pain and difficulty locking into his prosthesis, and excessive weight of the brace. In addition, the shoe he wore with the brace was badly deteriorated.

The treatment plan for this patient included a replacement prosthesis featuring suction suspension socket to improve on the existing pin lock mechanism, which can be difficult for older and impaired amputees to actuate, and a custom-molded ankle-foot orthosis (AFO) with custom shoe and insert. The prosthetist recommended a gel liner for protection of residual limb tissue, a particular concern given his osteomyelitis, and to aid suction. An Endolite Senior Foot was chosen for its light weight and simplicity of function.

Initial fitting and alignment went well; the patient was able to maintain excellent suction suspension in the prosthesis and reported no areas of excessive pressure in either the socket or the AFO. He demonstrated proper donning and doffing of both

devices. On follow-up a week later, the patient was confused about donning procedures for the prosthesis and was having difficulty managing the AFO and prescription shoe. The shoe insole was removed to create additional space; the AFO footplate and shoe would continue to provide needed protection.

Six weeks after initial component delivery and after several follow-up visits to align and adjust the componentry, the patient demonstrated reasonable ability to ambulate in his supportive devices. He then suddenly stopped walking and commenced bouncing up and down "to check his (prosthetic) leg" suspension, nearly losing his balance and falling as a result. Despite counseling, he insisted on periodically repeating that process, though his suction suspension was holding firm.

This patient's combination of physical limitations, visual impairment, and cognitive challenges are not uncommon in older diabetic amputees. His treatment team continues working with Philip to help him gain confidence in his ability to use his new componentry optimally and safely.

Note to Our Readers

Mention of specific products in our newsletter neither constitutes endorsement nor implies that we will recommend selection of those particular products for use with any particular patient or application. We offer this information to enhance professional and individual understanding of the orthotic and prosthetic disciplines and the experience and capabilities of our practice.

We gratefully acknowledge the assistance of the following resources used in compiling this issue:

Apex Foot Health Industries • Otto Bock Health Care
Ohio Willow Wood • Soletech

MOVING AHEAD

A Swanson Regional Orthotic & Prosthetic
Research Center publication

3102 Sylvania Ave. • Toledo, OH 43613
(419) 472-8910

124 Cole Rd. • Monroe, MI 48162
(313) 241-4397

735 S. Shoop Ave., Ste. 3 • Wauseon, OH 43567
(419) 335-6400

Vern Swanson, C.P. • Jon S. Eberlein, CPO

All contents copyright 2005

www.swansonopcenter.com

Swanson Regional Orthotic & Prosthetic Research Center

3102 Sylvania Ave. • Toledo, OH 43613