



# MOVING AHEAD

A Swanson Regional Orthotic & Prosthetic Research Center Publication

No. 42

Focus on...

## KAFOS

In this issue, we discuss knee-ankle-foot orthoses (KAFOs), long associated with child victims of poliomyelitis but now more commonly prescribed for spinal cord lesions, stroke and various neuromuscular diseases, notably spina bifida, some types of muscular dystrophy, and cerebral palsy.


A KAFO combines the functions of a knee orthosis and an AFO to control the knee during weight-bearing and provide

mediolateral ankle stability in stance phase and a plantar flexion stop during swing phase. It may be used to restrict knee motion to a specific range or eliminate it entirely. A KAFO provides support, corrects alignment, facilitates motion, and protects against injury for patients with common knee deformities: genu recurvatum, genu valgus, genu varum and flexion contractures.

The articles that follow will discuss contemporary KAFO applications and present two case studies. We hope you find the discussion worthwhile.

## Polio—'Summer Scourge' Not Gone Yet

Poliomyelitis (aka polio, infantile paralysis), the one-time summer scourge of communities across America, has now been all but eradicated in most of the world. Nevertheless, a great many survivors of the polio epidemics of



Plastics have changed the shape of polio KAFOs.

decades past are still with us—an estimated one million in the United States alone. The average age of polio survivors in the U.S. is nearing 70; those who were infants during the last major epidemic are well into middle age.

As the polio population ages, a puzzling and frustrating return and intensification of polio symptoms, once thought overcome, confront the medical community. Epidemiologic studies indicate some 22% of polio survivors will experience renewed muscle atrophy and weakness, pain, and other complications of post-polio syndrome (PPS).

### A New Challenge

PPS presents a unique set of challenges to orthotists. One-time polio sufferers who may have been getting along for years with either rudimentary, or a complete lack of, orthotic support may suddenly need a more-sophisticated system than the standard metal

### Orthotics 2000

leg brace design they may have been wearing since childhood.

Advancing muscle weakness in the PPS patient requires an optimal combination of orthosis strength, flexibility and light weight to make maximum use of the muscle strength that remains. It is therefore important that braces for patients experiencing PPS symptoms be custom-designed and fabricated for each patient's particular needs and residual capabilities.

*(Continued on page 2)*

### About Moving Ahead

**Moving Ahead** is a professional newsletter published by Swanson Regional Orthotic & Prosthetic Research Center to inform health care professionals of developments in the orthotic and prosthetic disciplines.

Swanson offers four board-certified practitioners and three state-of-the-art laboratories. The centers have a solid reputation for quality care and patient satisfaction throughout northwest Ohio and southeast Michigan and has been in business for more than 20 years.

To tour our well-equipped facilities or be added to our mailing list, please write or call:

**Swanson Regional Orthotic & Prosthetic Research Center**  
3102 Sylvania Ave. • Toledo, OH 43613 • (419) 472-8910

124 Cole Rd. • Monroe, MI 48162 • (313) 241-4397

1115 W. High St. • Bryan, OH 43506 • (419) 633-7304

Compliments of: Vern Swanson, C.P.; Jeffrey Kuehn, C.P.; Andrew Palmer, BOC Orthotist/C.Ped.; and Jon S. Eberlein, CPO.

# Post-Polio Syndrome Presents New Challenges

(Continued from page 1)

Typically, PPS patients wear KAFOs to assume weight-bearing loads and support paralyzed, deformed or unstable joints. The orthotic challenge is often to correct for drop foot, knee instability, reduced range of motion in both joints, and reduced muscle strength, all in one orthosis.

After decades of only limited improvement, the old standby steel-and-leather polio brace has been largely eclipsed by thermoplastic and plastic laminate designs that give PPS patients the required support and flexibility at less weight. With their progressive weakness and other symptoms, many patients reach a point where they can no longer get around with a heavy brace.

## But Will They Wear Them?

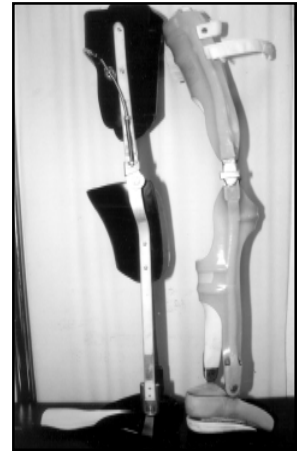Getting polio patients to accept this new generation of braces can be as much of a challenge as creating the brace in the first place. Patients who have been compensating for muscle weakness

the same way for decades typically do not want to change.

The key to, first, providing the optimal KAFO and, second, creating the best opportunity for patient acceptance of that orthosis resides in the skill and experience of the orthotist. Whether a polio patient needs new KAFOs because PPS has reduced his or her ability to function in the old ones or simply because the old braces are worn out, our orthotic staff will perform a thorough evaluation to determine the patient's present capabilities and understand both his or her daily activities and interests.

Then, because polio patients invariably recognize, and react to, the slightest design difference, our staff will make precise anatomical measurements and use the most appropriate components to create an orthosis in which the patient can feel comfortable and secure.

Two key factors in achieving acceptance of a new brace are patient education and participation in the orthotic process. Our continuing objective is to help our polio patients understand all pertinent advantages and disadvantages of any proposed new system, be aware of their choices, and actively participate in the decision-making process.



*Plastic laminate and thermoplastic KAFOs give improved support to PPS patients.*

## Componentry Capsule

**K**nee-ankle-foot orthoses (KAFOs) play a significant rehabilitation role for patients with lower-extremity weakness and joint instability secondary to upper and lower motor neuron lesions.

Though some KAFOs are still made from metal and leather, the majority of contemporary designs feature thermoplastic or laminated plastic construction with metal hinge joints. As compared

with metal orthoses, plastic designs generally offer comparable or greater support but are lighter in weight, distribute forces over a wider area, allow wearers to wear different

pairs of shoes, and are more cosmetically pleasing.

KAFOs come in various designs determined by the type of deformity and functional levels of the individual. The goal may be as basic as enabling a patient to achieve weight-bearing...or as involved as restoring functional ambulation. Our experienced orthotic staff can help determine the most appropriate design and construction for the goals and abilities of each patient.

Proper function of a KAFO frequently depends on achieving the optimal relationship between orthotic and anatomical structures, as well as among the various components of the orthosis itself. From a clinical perspective, optimal alignment is achieved when residual motor function is used as efficiently as possible with no undue stress on joints or compromise of walking safety. Approximate proper alignment is built into the orthosis during fabrication, then refined both statically and dynamically on the patient using various forms of gait analysis.

The design, fabrication, fitting and alignment of KAFOs requires dedicated, individualized attention for each patient to produce a positive functional outcome. We are dedicated to achieving the best result possible for each patient entrusted to our care and welcome your referrals.

## Helping Paraplegic

**T**he therapeutic benefits of enabling patients with lower-body neurologic impairment to stand and walk are well-established. Beyond the obvious improvement in mobility and psychological advantage of being able to relate to peers "on their level," achieving erect posture facilitates urinary tract drainage, thereby reducing infection risk; allows optimal lung function; stimulates the cardiovascular system; and boosts overall fitness. Orthopedically, erect weight-bearing helps increase bone density, controls development of contractures, prevents fixed deformities in the knees and feet, and in children may stimulate bone growth.

The reciprocating gait orthosis (RGO) has proven a viable modality for children whose horizons are limited by spina bifida, muscular dystrophy and related disorders, and for adult survivors of these conditions and spinal cord injuries. Though not a valid mobility alternative to a wheelchair when speed and range are important, an RGO gives appropriate patients the ability to ambulate in a more natural and efficient way than the awkward "swing-through" alternative.

The first reciprocating orthosis consisted of a cord-and-pulley modification to a young spina bifida patient's bilateral hip-knee-ankle-foot orthoses (HKAFOs). The mechanical linkage translated

# Down to Cases—Tethered Spinal Cord

**Presenting Status:** H.R., is a 26-year old female with a tethered spinal cord<sup>1</sup>, lower-extremity paresis resulting from surgery at age 15, and bilateral ligamentous tears. She presented wearing

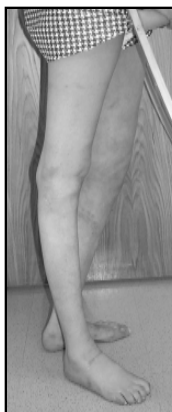bilateral semi-rigid plastic AFOs with Neoprene knee sleeves and using axillary crutches for ambulation. Her right knee displayed 25° genu recurvatum and 10° genu varum deformities; her left knee also was symptomatic due to a previous knee injury. Bilateral knee pain resulted in a pronounced antalgic gait.

## Gross Motor Assessment

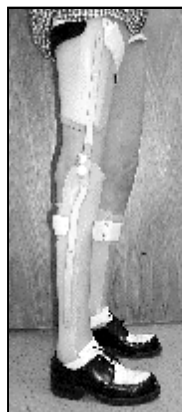1. (B) flail ankles
2. 3-/5 knee extensors
3. 2/5 knee flexors
4. 2-/5 hip extensors
5. 3/5 hip flexors
6. 3/5 hip adductors
7. 1+/5 hip abductors

**Orthotic Objectives:** H.R.'s orthotist determined that an appropriately designed KAFO could alleviate the pain and instability of the patient's right knee and that a new AFO could enhance stability of the left leg.

**Orthotic Design:** The thermoplastic KAFO features an anterior-entry femoral shell with a removal liner and polycentric, free-motion knee joints to accommodate the patient's shifting knee joint axis. The lower section consists of a posterior-entry pre-tibial shell and rigid ankle. H.R.'s redesigned left AFO provides a better fit and more rigidity in



*H.R. without orthosis and in her new KAFO.*



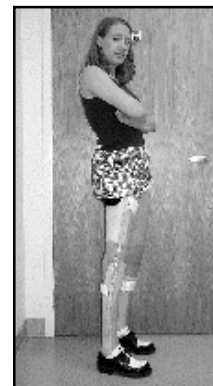the ankle, producing significantly better knee control.

**Outcome:** These new orthoses have considerably improved H.R.'s balance and overall stability—she is now able to stand without having to hold on to fixed objects for support, a new experience for her. On follow-up she reported all pain in her right knee had been eliminated. She also commented that she has a far greater sense of confidence and security when ambulating.

## Notes

<sup>1</sup>**Tethered cord** describes a condition in which the spinal cord is abnormally fastened to an immovable structure such as a lipoma (fatty mass), vertebra, dura (the membrane covering the spinal cord) or skin. The spinal cord is then fixed between two points: first at the tethering structure and second at the base of the brain. Thus, vertebral structures that move as a result of growth, daily activity, or pathological skeletal change (scoliosis or curvature of the spine) will stretch the spinal cord abnormally. The result is that this segment of tethered cord is stretched beyond its tolerance, damaging blood vessels, nerve cells, and nerve fibers.

**Etiology**—Tethering of the spinal cord can result from presence of bony protrusions or tough membranous bands that prevent the cord from moving, as well as lipomas and tumors (mostly benign), myelomeningocele, cysts, scarring and trauma.



*Look: No hands!*

## cs Arise and Walk

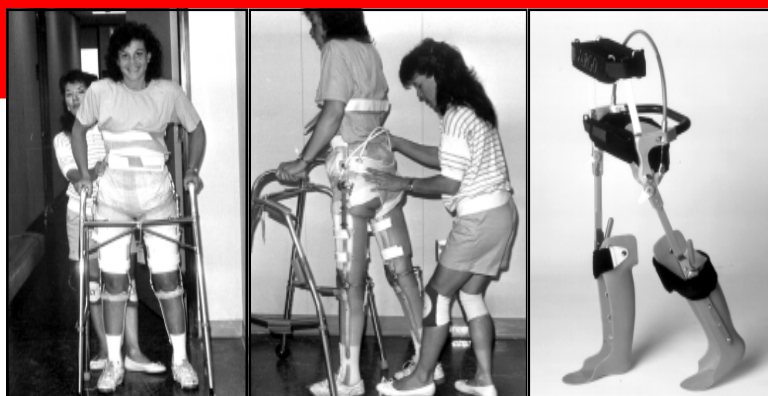hip flexion on one side into hip extension on the contralateral side.

A subsequent design derivation, the Louisiana State University RGO, consists of bilateral HKAFOs connected by a custom-molded thermoplastic pelvic girdle (or metal band) and dual cables cross-connected to thrust-bearing hip joints on the opposite side. Rhythmic actuation of the cables induces hip flexion on alternating sides, establishing the reciprocal gait pattern.

Newer RGO concepts improve efficiency and reduce energy expenditure in producing reciprocal hip motion.

- The Fillauer Horizontal Cable System replaces the characteristic LSU hooped cables with bilateral rocker arms linked to the hip joints and connected to each other at the corresponding ends by teflon-coated cables. Patients who have worn both designs cite the Fillauer system's smoother action, which translates into easier walking, and its trim cosmesis.

- The Advanced Reciprocating Gait Orthosis (ARGO) employs a single low-friction, push-pull cable to effect reciprocal gait locomotion. In addition to the standard adult version, an ARGO Junior model featuring brightly colored AFOs and hip lock levers that resemble a duck's head is offered for children age 2-6 years. The adult version incorporates gas struts on the



*LSU reciprocating gait orthosis in action.*

*ARGO Jr.*

leg braces and automatic knee-lock cables, which combine to provide a substantial assist when rising to a standing posture and a braking system when sitting.

- The Isocentric® Reciprocating Gait Orthosis (IRGO) is a significant departure from other designs, using a centrally pivoting bar and tie rod arrangement in lieu of cables to link hip extension to contralateral hip flexion. Absence of cables reduces friction in the system by as much as 2-3 times.

These innovative newer designs are taking the RGO to a new levels of performance, appearance and user-friendliness. Each offers specific advantages, depending on patient capabilities and needs. For more information on RGOs, call our office.

# Down to Cases — Arthrogryposis

**Presenting Status:** B.W. is a 28-year-old male with a diagnosis of arthrogryposis<sup>1</sup>, triple arthrodeses and knee flexor releases. When referred for orthotic management, he was wearing bilateral leather and metal KAFOs with solid plastic AFO lower sections, metal bands/leather cuff upper sections and intrinsic heel elevations. He demonstrated external tibial rotation and ambulated

## Gross Motor Assessment

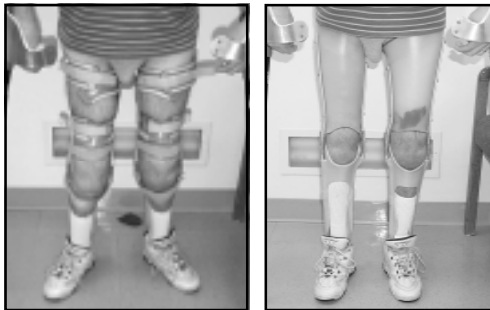
1. (B) flail ankles
2. 3-/5 knee extensors
3. 3/5 knee flexors
4. 3-/5 hip extensors
5. 3/5 hip flexors
6. 3/5 hip adductors
7. 1+5 hip abductors

with a reciprocating four-point gait using modified Lofstrand crutches. His feet are deformed, rigid and bony, ankles are surgically fixed at 20° plantar flexion, and knees exhibit A-P and M-L laxity. KAFO straps were worn loose to combat skin integrity compromise.

**Orthotic Objective:** B.W., a computer programmer, was reasonably functional at work in his old-style orthoses; however, he felt considerably limited in leisure activities. He was referred for new orthoses to enable him to ambulate with less energy expenditure and resolve ongoing skin breakdown issues at the lateral border of his right foot, over his proximal tibias and posteriorly at the proximal thigh bands, where he also had developed soft tissue deformities.

**Orthotic Design:** After thorough evaluation, B.W.'s orthotist

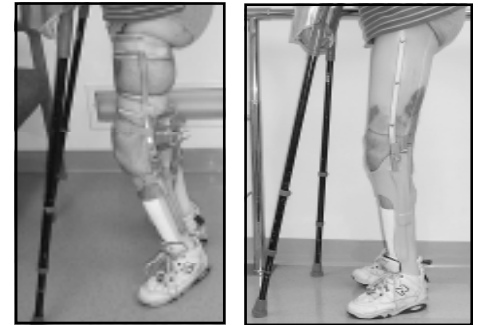
recommended thermoplastic/laminate KAFOs with narrow M-L femoral shells, bail lock knee joints, and very rigid laminated lower sections including pretibial shells. The femoral section



*Old orthoses (left), new KAFOs*

design provides circumferential and ischial weight-bearing to achieve partial unloading of the feet and knees, as well as soft tissue confinement with even pressure distribution. The bail locks engage automatically and can be released with one hand. The pretibial shells contribute superior proximal tibial control, increase knee stability and eliminate need for straps or buckles.

**Outcome:** The most obvious benefit of the new KAFOs is that B.W. now stands two inches taller while wearing them! He stands and ambulates with greater stability and balance, less pain and greater endurance; skin breakdown has virtually disappeared.



*Sagittal view: Old and new.*

The ischial containment shells do restrict some movements, such as “scotching” laterally while seated on a bench or sofa, but the patient considers the trade-off for the improved stability, balance, tolerance and skin health to be well worth that limitation.

## Notes:

<sup>1</sup> **Arthrogryposis**—A syndrome complex characterized by multiple joint contractures (especially of the upper limbs and neck) without other serious congenital abnormalities and with relatively normal intelligence. When there is generalized fixation or ankylosis of joints at birth, it is termed arthrogryposis multiplex congenita (AMC), but it can also occur as an isolated finding. Incidence is estimated at one in 3000 live births.

**Etiology**—Joint development occurs in the second month of gestation—disorders that impair in utero movement (e.g. uterine malformations, multiple gestations, oligohydramnios) can result in arthrogryposis. AMC can also result from neurogenic, myopathic, or connective tissue disorders. Congenital myopathies, anterior horn cell disease, and maternal myasthenia gravis have been proposed as causes of the associated amyoplasia. AMC is not genetic, although genetic disorders (e.g., trisomy 18, spina bifida) have an increased incidence of arthrogryposis.

## Swanson Regional Orthotic & Prosthetic Research Center

3102 Sylvania Ave. • Toledo, OH 43613

### MOVING AHEAD

A Swanson Regional Orthotic & Prosthetic Research Center publication

3102 Sylvania Ave. • Toledo, OH 43613  
(419) 472-8910

124 Cole Rd. • Monroe, MI 48162  
(313) 241-4397

1115 W. High St. • Bryan, OH 43506  
(419) 633-7304

Vern Swanson, C.P. • Jeffrey Kuehn, C.P.  
Jon S. Eberlein, CPO

All contents copyright 2000